

CASE REPORT

Point-of-Care Ultrasound Findings in a Case of Botfly Myiasis Contracted in the United States

Christopher A. Davis, MD¹; Jasmine Patterson, MD²; Katarzyna A. Hampton, MD³

¹Wake Forest University School of Medicine, Department of Emergency Medicine, Winston-Salem, NC; ²USF Department of Internal Medicine, Division of Emergency Medicine, Tampa General Hospital, Tampa, FL; ³Washington University in St. Louis, EMS Division, St. Louis, MO

Botfly infiltration is a rare cause of pediatric skin manifestations in the United States, but should be considered in nonhealing wounds even in nontravelers. We describe the case of a healthy 6-y-old female who had never traveled outside of the southeast United States, presenting with a nonhealing skin lesion. The point-of-care ultrasound (POCUS) findings suggested subcutaneous parasitic infiltration. This case demonstrates the role of POCUS in identification of subcutaneous parasitic infiltration, and differentiation from other, more common skin lesions.

Keywords: Dermatobia, cuterebra, myiasis, POCUS

Introduction

Infiltration of human tissue by a fly larva is called myiasis.¹⁻⁵ The most common site for infiltration is the skin. Presentations include furuncular, wound, and migratory myiasis.¹ Several fly species can cause human myiasis, but the human botfly, *Dermatobia hominis*, is the only species of botfly whose larvae ordinarily parasitize humans.¹ Most cases of human furuncular myiasis seen in the United States are caused by the human botfly and are acquired during travel in Central and South America. When the infiltration is acquired in the United States, rodent botfly larvae from the genus *Cuterebra* are among the most commonly implicated species.⁴ The rodent botfly is an obligate parasite of squirrels, mice, and rabbits.¹ The adult fly lays its eggs on foliage. If a human inadvertently comes into contact with an egg, the heat of the skin causes the egg to hatch. Once hatched, the larva burrows under the skin to complete its life cycle.

Patients infiltrated with botfly larvae typically present with a red, indurated area that may be painful or itchy. When there is no history of travel to endemic areas, these lesions are typically diagnosed as abscesses or cellulitis and treated with antibiotics, only for treatment to fail. Use of point-of-care ultrasound (POCUS) allows clinicians to directly visualize an area of cellulitis and differentiate it from an abscess. The extent of an abscess can be determined with POCUS, which aids in the decision whether to drain it surgically. POCUS can also demonstrate other subcutaneous lesions. Application of color Doppler interrogation helps detect vascular flow within a lesion, aiding the diagnosis. Presence of a rod-like shaped apparently vascular structure may suggest a larva, and guide the clinician toward asphyxiation techniques for removal, rather than incision and drainage.

Case Report

A 6-y-old girl presented to the emergency department (ED) with 5 d of an itchy, red skin rash on the left upper chest wall. She was a long-term resident of North Carolina and had not recently traveled outside of the state, had no fever or constitutional symptoms and had otherwise been well. On her presentation to the ED, she had normal vital signs. On physical exam, there were 2 lesions on the left upper chest wall resembling insect “stings” with surrounding redness and induration but no

Corresponding author: Christopher A. Davis, MD, Assistant Professor of Emergency Medicine, Wake Forest University School of Medicine, Meads Hall 2nd Floor, 1 Medical Center Blvd, Winston Salem, NC 27157; e-mail: christda@wakehealth.edu.

Submitted for publication November 2021.

Accepted for publication April 2022.

© 2022 Wilderness Medical Society. Published by Elsevier Inc. All rights reserved.

<https://doi.org/10.1016/j.wem.2022.04.004>

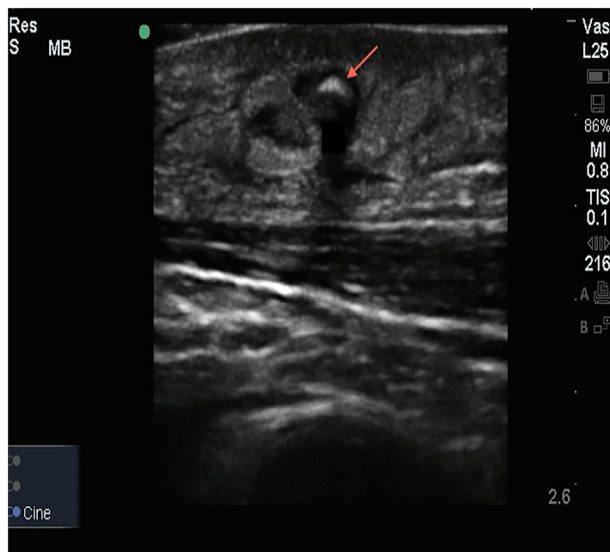


Figure 1. Ultrasound images of skin lesion containing cutaneous bot fly larva (arrow) with posterior shadowing and surrounding inflammatory changes (cobblestone appearance) but no abscess cavity.

fluctuance. No retained stinger was seen. The patient was treated for presumed cellulitis with a 10-d course of clindamycin.

She returned to the ED in 7 d. The area had initially improved, but now had become irritated again and drained a small amount of serous fluid. She had remained afebrile, with no other symptoms and had continued to take her antibiotic as prescribed. On this second visit, she had a punctate lesion with a black center on her left upper chest and a 1.5 cm area of surrounding redness and induration but no fluctuance. No fluid could be expressed from the punctum. POCUS examination of the area in question was performed. A rod-like echogenic structure with posterior shadowing in a hypoechoic cavity was noted. Color Doppler was not used (Figure 1). The family did not recall any injury that could have left a residual foreign body, but they did think it was possible that an insect had stung her.

There was no stinger visible in the skin on the first or second visit. The treating physicians felt the reddened area might be a sign of fat necrosis from the prior infection or more likely might be a foreign body based on the ultrasound findings. The family was instructed to cover the wound with antibiotic ointment, finish the oral antibiotic course, and follow up with a pediatric surgical specialist if the wound did not heal within the next several days.

The following day, during wound care, the family noted the punctate central area had opened slightly and drained serous fluid. Coincidentally, the family had a

previously scheduled well-child check with their pediatrician that day. During that visit, the pediatrician noticed the central opening of the reddened area on the patient's upper chest. When the pediatrician squeezed the surrounding skin, there was movement in the opening of the reddened area. The pediatrician probed the opening and used forceps to remove a small white larva. The larva was preserved in alcohol and later identified as the second instar (larva) of a fly in the genus *Cuterebra*, likely a squirrel botfly. The patient fully recovered. Her wound healed without a scar.

Discussion

The infiltration of living, human tissue by a fly larva is termed myiasis. Myiasis is classified clinically according to the type of body tissue involved. The most common type of myiasis is cutaneous myiasis. Presentations include furuncular, migratory, and wound myiasis.^{4,6}

Human and rodent botfly larvae typically produce single lesions. Myiasis from other species may present with multiple lesions.⁴ Local inflammation can cause itching. Patients may also describe lancinating pain at night or may feel movement in the skin.⁷⁻⁹ Normally, patients are not ill. However, certain species of botfly such as *Cordylobia rodhaini*, found in sub-Saharan Africa, can lay multiple eggs causing a systemic inflammatory reaction with fever and lymphadenopathy.⁸ Initial presentations are typically attributed to skin infections such as cellulitis or abscesses. In a patient with a nonhealing wound, clinicians should consider botfly infiltration in the differential diagnosis.¹⁰ While a history of travel makes the diagnosis more likely, this case illustrates that it is not required. In the United States, most accidental human infiltrations occur in the northeast.¹ To our knowledge, there is only 1 prior report of furuncular myiasis acquired in North Carolina.¹

POCUS is used frequently in EDs and in some clinics.¹¹ In a furuncle, a botfly larva appears on ultrasound as a hyperechoic line with posterior shadowing and no abscess cavity⁵ (Figure 1). Often, the body segmentations are visible. On live imaging, movement may be detected, and on color Doppler vascular flow may be seen.¹²

Removal of a botfly larva can be accomplished by asphyxiating it with an ointment, nail polish, or pork fat. This forces the larva to emerge through its breathing hole, allowing it to be grasped with forceps. The surrounding furuncle can be squeezed to help with the expulsion of the larva.^{8,10} Surgical removal with simple incision and drainage may be necessary if the patient presents later in the course of larval development or is so distraught that

waiting for asphyxiation would cause undue emotional distress.⁴ Fortunately, botfly larvae release bacteriostatic substances that make infection unlikely. Although antibiotics are sometimes necessary to treat secondary bacterial infections, there is no need for prophylactic antibiotics.⁴ Most patients recover uneventfully after the removal of a larva.⁴

Conclusions

We report an unusual case of botfly infiltration in a region where it is uncommon. In areas where botfly myiasis is common, the diagnosis is usually apparent based on history and physical exam. In this case, the clinicians did not make the diagnosis of botfly myiasis on the first 2 presentations to the ED despite characteristic findings on POCUS. Failure to make the diagnosis was likely caused by a lack of familiarity with botfly myiasis. This case illustrates that it is possible to acquire botfly myiasis in the United States. Familiarity with the characteristic ultrasound findings may help clinicians recognize this condition.

Acknowledgments: We thank Katharina Dittmar, PhD, Associate Professor, Department of Biological Science, University at Buffalo, for her help identifying the botfly larvae.

Author Contributions: Data acquisition (CAD, JP, KH); drafting and critical revision of the manuscript (CAD, JP, KH); and approval of final manuscript (CAD, JP, KH).

Financial/Material Support: None.

Disclosures: None.

References

1. Safdar N, Young DK, Andes D. Autochthonous furuncular myiasis in the United States: case report and literature review. *Clin Infect Dis*. 2003;36(7):e73–80.
2. Baird CR, Podgore JK, Sabrosky CW. *Cuterebra* myiasis in humans: six new case reports from the United States with a summary of known cases (Diptera: Cuterebridae). *J Med Entomol*. 1982;19(3):263–7.
3. Baird JK, Baird CR, Sabrosky CW. North American cuterebrid myiasis. Report of seventeen new infections of human beings and review of the disease. *J Am Acad Dermatol*. 1989;21(4 Pt 1):763–72.
4. McGraw TA, Turiansky GW. Cutaneous myiasis. *J Am Acad Dermatol*. 2008;58(6):907–26.
5. Minakova E, Doniger SJ. Botfly larva masquerading as periorbital cellulitis: identification by point-of-care ultrasonography. *Pediatr Emerg Care*. 2014;30(6):437–9.
6. Langhan ML. The 2007–2008 photo competition award winner: Melissa Langhan, MD: a painful scalp rash: cutaneous myiasis secondary to new world screwworm. *Pediatr Emerg Care*. 2008;24(7):502–4.
7. Maier H, Hönigsmann H. Furuncular myiasis caused by *Dermatobia hominis*, the human botfly. *J Am Acad Dermatol*. 2004;50(2 Suppl):S26–30.
8. Veraldi S, Serini SM, Süß L. Three cases of cutaneous myiasis caused by *Cordylobia rodhaini*. *J Infect Dev Ctries*. 2014;8(2):249–51.
9. Whitcomb V, Hartwig E. An unexpected guest: a case of cutaneous furuncular myiasis: the 2013 PEMpix photo competition winner. *Pediatr Emerg Care*. 2016;32(3):183–4.
10. Bhandari R, Janos DP, Sinnis P. Furuncular myiasis caused by *Dermatobia hominis* in a returning traveler. *Am J Trop Med Hyg*. 2007;76(3):598–9.
11. O'Brien AJ, Brady RM. Point-of-care ultrasound in paediatric emergency medicine. *J Paediatr Child Health*. 2016;52(2):174–80.
12. Richter J, Schmitt M, Müller-Stöver I, Göbels K, Häussinger D. Sonographic detection of subcutaneous fly larvae in human myiasis. *J Clin Ultrasound*. 2008;36(3):169–73.